

CASE REPORT

**SEVERE HYPERSENSITIVITY SYNDROME ASSOCIATED WITH REACTIVATION
OF HUMAN HERPESVIRUS-6 VARIANT B**

Maria Isabel de Oliveira¹, Cristina Adelaide Figueiredo¹, Ana Maria Sardinha Afonso¹, Felipe Maia de Toledo Piza²; Márcia Theobaldo¹; Jamal M. Suleiman², Suely Pires Curti¹

¹Instituto Adolfo Lutz, Divisão de Biologia Médica, Serviço de Virologia; São Paulo, Brasil.

²Instituto de Infectologia Emilio Ribas, São Paulo, Brasil.

Corresponding author:

Maria Isabel de Oliveira, Instituto Adolfo Lutz, Divisão da Biologia Médica, Serviço de Virologia. Av. Dr. Arnaldo 355, Cerqueira César, Cep 01246-902, São Paulo, SP, Brasil.

Tel: +55 11 3068-2994

Fax: +55 11 3088-3753.

E-mail: olive40@uol.com.br

Key words: phenytoin, human herpes virus-6, hypersensitivity syndrome.

ABSTRACT

A 24 year-old patient presented with an adverse reaction to phenytoin therapy associated with drug-induced hypersensitivity syndrome, suggesting a relationship to a reactivation of human herpesvirus 6. The investigation of viral infection was done by antiHHV-6 IgM, IgG serology and PCR. The sequence was analyzed and it was identified as HHV-6 variant B.

INTRODUCTION

The human herpesvirus-6 (HHV-6) is a member of the β -herpesvirus family. There are two variants of HHV-6, A and B. While the epidemiology and clinical significance of HHV-6 variant A remains elusive, the B variant has been definitively linked to *exanthema subitum*. This is a common virus that infects the majority of the population in early childhood and establishes latency thereafter (Aubin et al. 1994)

A relationship between viral infections and the simultaneous or subsequent development of allergic inflammation has been observed in several clinical situations, suggesting an intimate relationship between reactivation of herpes viruses including HHV-6, and the development of a severe systemic hypersensitivity reaction referred to drug-induced hypersensitivity syndrome (DIHS) (Shiohara et al. 2006). Although the immune responses to viruses include multiple immune cells, innate immune responses are of particular importance because of their central role in both providing a rapid antiviral host defense and determining the nature of downstream adaptive immune responses. One favored hypothesis is that allergic disorders frequently associated with viral infections are manifestations of dysfunction of innate immunity. However, it is difficult to demonstrate that the innate cell's dysfunction in viral infections results in the development of allergic diseases, because the specific contribution of any single virus to the particular allergic disease has not been demonstrated. (Tohyama et al 1998, Descamps et al. 2001)

In this paper we have studied the clinical symptoms of DIHS and the possible etiologic role of herpes viruses, including HHV-6, in the development of this syndrome.

MATERIAL AND METHODS

We report the case of a 24 year-old male who presented with convulsions and who had been treated with phenytoin; three weeks after discontinuing the use of the drug, the patient showed a dramatic response with high fever and a generalized maculopapular rash that continued for two weeks, after which he recovered from the syndrome.

The diagnostic criteria were the analysis of white blood cell count and microscopic examination of a skin biopsy of a lesion on the upper portion of the right arm of the patient. Serological testes have been processed to detect specific IgG and IgM antibody to measles, rubella, toxoplasmosis, cytomegalovirus, rickettsia, dengue, and hepatitis A, B, C virus. Quantitative polymerase chain reaction (PCR) to detect HIV has been also applied to the patient's serum.

The human herpesvirus 6 (HHV6) serology was performed using an indirect immunofluorescence assay - IFA (Biotrin, Dublin, Ireland) and peripheral blood mononuclear cell (PBMC) samples were collected. Viral DNA was extracted by using PureLink Viral RNA/DNA Mini Kit (Invitrogen) and amplified by PCR – already defined on p.3 followed by nested PCR using specific primers to amplify HHV-6 as described by Huang et al. (1992). The PCR products were sequenced directly using the “ABI Prism Big Dye Terminator v3.1 Cycle Sequencing Ready Reaction Kit” according to the manufacturer's protocol. Sequences were determined in an ABI sequencer model 377.

Sequence alignment was performed using the multiple sequence alignment method implemented in CLUSTALX11 and DNASTar, Inc. software package.

RESULTS

The diagnosis was confirmed by the presence of the following criteria: maculopapular rash developing >3 weeks after starting therapy with the offending drug, lymphadenopathy, fever >38⁰C, leukocytosis (>10X 10⁹/L), atypical lymphocytosis, eosinophilia and hepatitis (ALT>100U/L). A skin biopsy specimen (Figure1) showed lymphocytic infiltration, necrotic keratinocytes and partial liquefaction degeneration of basal cells.

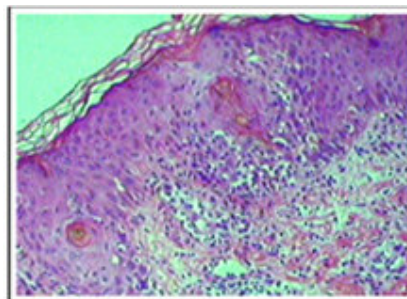


Figure 1. Skin sample showing necrotic keratinocytes, partial liquefaction and degeneration of basal cells in the epidermis, and perivascular infiltration of lymphocytic cells in the dermis (H&E 100x)

The serological test to detect specific IgM and IgG antibodies to other viruses showed negative results. Quantitative PCR to detect DNA of HIV was also negative. The blood sample was then tested for HHV-6 infection, presenting anti HHV-6 IgG positive and anti HHV-6 IgM negative serology. Nested-PCR analysis to detect HHV-6 virus was positive, as shown in Figure 2, with the amplification of 214pb. This result was considered the gold standard. The sequence was analyzed and compared with other strains of HHV-6 from the GenBank that represented variant B.

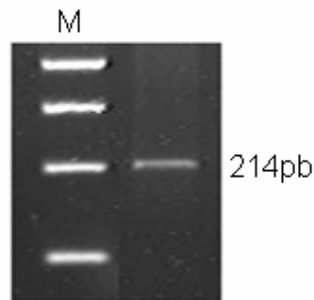


Figure 2. Agarose gel electrophoretogram showing the sensitivity of the common primers used in nested PCR targeting the gene of HHV-6. M indicates the molecular weight standard marker.

DISCUSSION

Most people are infected with HHV-6 in early childhood. The HHV-6 latently infects monocytes and salivary glands. The mechanism and reactivation of HHV-6 are unknown. In immunocompromised patients, it appears that the reactivation of HHV-6 is not infrequent (Okuno et al. 1990, Calligaris et al. 2009).

In this case report the patient with DIHS had probably reactivation of HHV-6 as he recovered after discontinuing the offending drug. A drug-associated hypersensitivity syndrome has been reported with the administration of anticonvulsants (phenytoin, phenobarbital, carbamazepine) and several other drugs. (Han et al. 1969, Sotolongo et al. 1978, Vittorio et al 1995, Yao et al. 2008).

Recent studies reported a relationship between HHV-6 reactivation and the development of this syndrome. Such studies suggest that HHV-6 reactivation is a consequence of cell activation occurring during the course of drug eruptions (Shiohara 2008). The HHV-6 reactivation was evidenced by the rise in HHV-6 IgG titers since HHV-6 virus DNA levels appear generally 2-3 weeks after the onset of rashes in the vast majority of patients with DIHS, as

shown in our study. Our finding from a microscopic examination of a skin fragment showing atypical lymphocytes and eosinophilia of various degrees is also a prominent feature of this syndrome.

The HHV-6 reactivation was evidenced by the rise in HHV-6 IgG titers and HHV-6 DNA. The evaluation of HHV-6 antibody titers is controversial. A marked increase in anti HHV-6 IgG titers strongly indicates a primary or reactivated infection of HHV-6. In general, the appearance of anti HHV-6 IgM suggests primary infection, while a remarkable increase in IgG titers without IgM antibodies indicates reactivated HHV-6 infection. However, PCR analysis is more sensitive, detecting HHV-6 DNA in 49% to 88% of PBMCs in healthy seropositive adults (Shiohara et al. 2006).

In this case we could observe the reactivation of HHV-6, which is correlated with group B, helping to confirm the identification of this syndrome. Genotyping of HHV-6 is important to determine the group of virus that is circulating, to monitor HHV-6 infection in transplants or to establish the diagnosis of patients with neurological diseases and multiple sclerosis.

It is noteworthy that DIHS must be considered in patients who after using anticonvulsant drugs for 3 weeks, present compatible symptoms. This is vital because the mortality rate may reach 40% and because these drugs – especially phenytoin – are widely used with epileptic patients. After diagnosis has been confirmed, the patient must be advised to discontinue these drugs. Furthermore, to avoid similar future problems, the whole family must be equally advised to carry out the Lymphocyte Transformation Test (LTT) since other family members may be under risk to present the same syndrome (Calligaris et al. 2009, Shiohara et al. 2006, Quinones et al. 1999).

This report showed the importance of reviewing allergic diseases that might be caused by drug therapies. Laboratory analyses are a useful tool to help elucidate the reactivation of HHV-6 in DIHS in order to achieve full understanding of the complex role played by a viral infection in allergic diseases.

REFERENCES

Aubin JT, Poirel L, Robert C, Huraux JM, Agut H 1994. Identification of human herpesvirus 6 variants A and B by amplicon hybridization with variant-specific oligonucleotides and amplification with variant-specific primers. *J. Clin. Microbiol.* 32: 2434-2440.

Calligaris L, Stocco G, De Iudicibus S, Marino S, Decorti G, Barbi E, Carrozzi M, Marchetti F, Bartoli F, Ventura A 2009. Carbamazepine hypersensitivity syndrome triggered by a human herpes virus reactivation in a genetically predisposed patient. *Int. Arch. Allergy Immunol.* 149: 173-177.

Descamps V, Valance A, Edlinger C, Fillet AM, Grossin M, Lebrun-Vignes B, Belaich S, Crickx B 2001. Association of human herpesvirus 6 infection with drug reaction with eosinophilia and systemic symptoms. *Arch. Dermatol.* 137: 301-304.

Han T, Chawla PL, Sokal JE 1969. Sulfapyridine-induced serum-sickness-like syndrome associated with plasmacytosis, lymphocytosis and multiclonal gammaglobulinopathy. *N. Engl. J. Med.* 280: 547-548.

Huang LM, Kuo PF, Lee CY, Chen JY, Liu MY, Yang CS 1992. Detection of human herpesvirus-6 DNA by polymerase chain reaction in serum or plasma *J. Med. Virol.* 38: 7-10.

Okuno T, Higashi K, Shiraki K, Yamanishi K, Takahashi M, Kokado Y, Ishibashi M, Takahara S, Sonoda T, Tanaka K 1990. Human herpesvirus 6 infection in renal transplantation. *Transplantation* 49: 519-522.

Quiñónez MD, Valero C, Salcedo M, Sanchez I, Jerez J, Matorras P. 1999. Phenytoin hypersensitivity syndrome with fatal evolution. *Allergy.* 54: 83-84.

Shiohara T, Inaoka M, Kano Y 2006. Drug-induced hypersensitivity syndrome (DIHS): a reaction induced by a complex interplay among herpesviruses and antiviral and antidrug immune responses. *Allergology International* 55: 1-8.

Sotolongo RP, Neeffe LI, Rudzki C, Ishak KG 1978. Hypersensitivity reaction to sulfasalazine with severe hepatotoxicity. *Gastroenterology* 75: 95-99.

Tohyama M, Yahata Y, Yasukawa M, Inagi R, Urano Y, Yamanishi K, Hashimoto K 1998. Severe hypersensitivity syndrome due to sulfasalazine associates with reactivation of human herpesvirus 6. *Arch Dermatol.* 134: 1113-1117.

Vittorio CC, Muglia JJ 1995. Anticonvulsant hypersensitivity syndrome. *Arch. Intern. Med.* 155: 2285-2290.

Yao K, Gagnon S, Akhyani N, Williams E, Fotheringham J, Frohman E, Stuve O, Monson N, Racke MK, Jacobson S 2008. Reactivation of human herpesvirus-6 in natalizumab treated multiple sclerosis patients. *PLoS One* 3: 1-7.